



# COOPERATIVE EXTENSION

*Bringing the University to You*

---

SP-00-08

## Equine Dentition

Al Cirelli, Extension Horse Specialist, School of Veterinary Medicine

### Introduction

Providing routine dental care is important to the development of healthy horses. A sound mouth can help prevent against the incidence of digestive problems such as colic, weight loss and poor feed utilization. A good mouth is also important to the success of performance horses; for example, a horse with hooks (enamel points on edges of upper or lower molars) may not be able to slide the lower jaw forward to close the angle at the throat latch when asked to flex at the poll.

Additionally, the manner in which a horse is maintained can influence the condition of the mouth. Horses on pasture are able to use their teeth and jaws naturally in a way providing for efficient function. The natural action of using the incisors to tear or cut the grass and the molars to grind it allows the jaws to be used with a full range of motion, thereby providing an advantage over stabled horses. In the case of a stabled horse, there is little natural wear of the incisors because of lack of ability to tear or crop grass. Consequently these teeth can grow too long and decrease the contact between the molars of the lower and upper jaws. Grinding becomes less efficient resulting in the development of hooks, (sharp enamel points) and the condition known as wave mouth. This results in less efficient digestion and feed utilization. Pelleted and cubed diets can inhibit the normal chewing motion which may result in abnormal mouth conditions of stabled horses.

### Dentition:

Young horses have a total 24 deciduous or milk teeth - 12 incisors and 12 premolars or grinders. Mature male horses have 40-42 permanent teeth and mares have 36-40 depending on the number of canine teeth present Table 1. Canine or bridle teeth erupt in the inter dental space at 4-5 years of age in male horses. They will only appear 20-25% of the time in mares and are usually smaller than those found in males. The first premolar (wolf-tooth) may be absent or rudimentary. In most horses it is only present in the maxillary (upper) jaw.

**Table 1. Dental Formula**

Male	Female
$2 \left( \overset{3}{\text{I}} \overset{1}{\text{C}} \overset{3 \text{ or } 4}{\text{P}} \overset{3}{\text{M}} \right) = 40 - 42$	$2 \left( \overset{3}{\text{I}} \overset{0}{\text{C}} \overset{3 \text{ or } 4}{\text{P}} \overset{3}{\text{M}} \right) = 36 - 40$

I = Incisors, C = Canines, P = Premolars, M = Molars

**Table 2. Appearance of deciduous and permanent equine teeth**

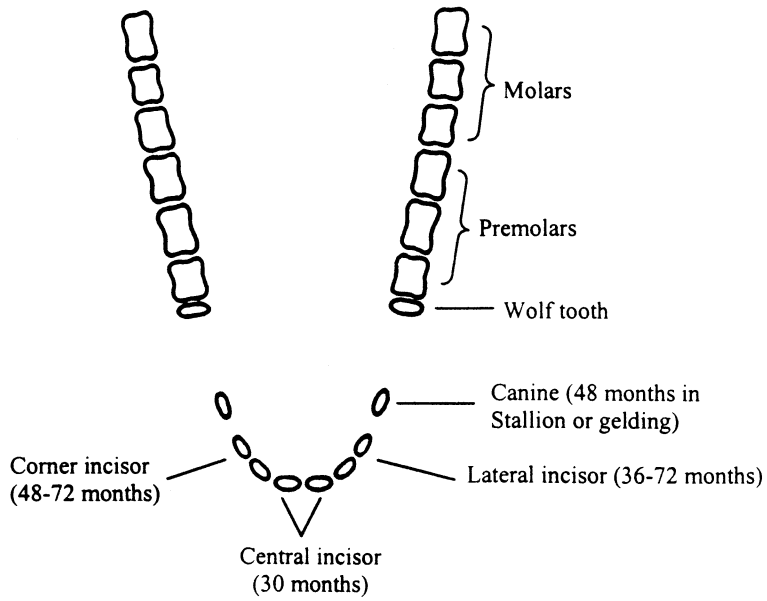
**Time of Appearance**

Tooth	Deciduous	Permanent
1 <sup>st</sup> Incisor	Birth-1 <sup>st</sup> Wk.	2.5 Yrs.
2 <sup>nd</sup>	6-4	3.5
3 <sup>rd</sup>	6-9 Mos.	4.5
Canine		4-5
1 <sup>st</sup> Premolar (wolf tooth)		5-6 Mos.
2 <sup>nd</sup>	Birth-2 <sup>nd</sup> Wk.	2.5 Yrs.
3 <sup>rd</sup>	Birth-2 <sup>nd</sup>	3
4 <sup>th</sup>	Birth-2 <sup>nd</sup>	3.5
1 <sup>st</sup> Molar		9-12 Mos.
2 <sup>nd</sup>		2 Yrs.
3 <sup>rd</sup>		3.5-4

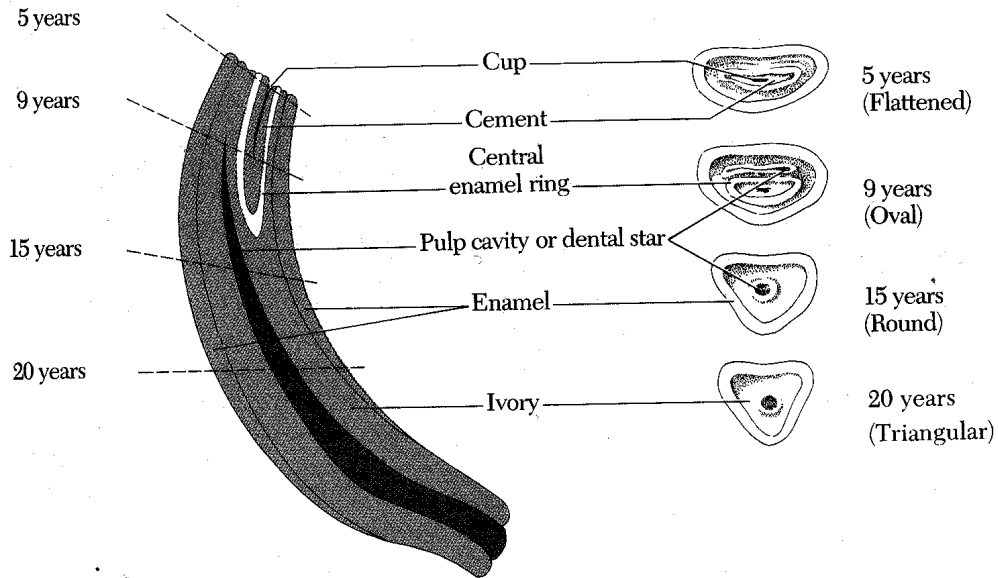
At approximately 5 years of age and when all permanent teeth have erupted, the horse is said to have a "full mouth" (Figure 1).

Continued growth and wear of the incisor teeth results in changes of shape and appearance that allow them to be useful in age determination.

**Figure 1. View from above**



**Figure 2. Anatomy of equine incisor tooth**



**Table 3. Disappearance of cups from incisor teeth**

Age (Yrs.)	Incisors					
	Lower			Upper		
	Central	Intermediate	Corner	Central	Intermediate	Corner
	<u>6</u>	<u>7</u>	<u>8</u>	<u>9</u>	<u>10</u>	<u>11-12</u>

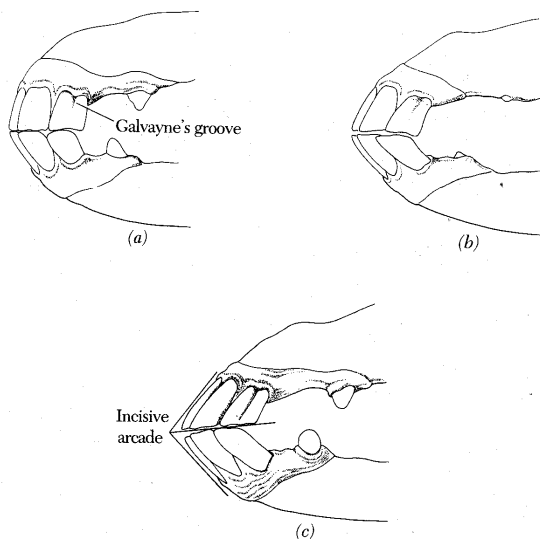
At 11 or 12 years of age when cups are absent from all lower and upper incisors the horse is said to be "smooth-mouthed".

With practice, one can become proficient when estimating ages between 6 and 12 years by using the presence or absence of the cups in the incisors. When the horse is older than 12 years, it is difficult to estimate age of the horse and accuracy decreases.

To age an older horse the following should be used (Figure 3).

- (1) Incisive Arcade: The angle formed between lower and upper incisors becomes more acute with age.
- (2) Table Surface Shape: As age advances the surface changes from rectangular to triangular in shape.
- (3) Galvayne's Groove on Upper Corner Incisors:

**Figure 3. Profile of upper corner incisor, incisive arcade, and Galvayne's groove**

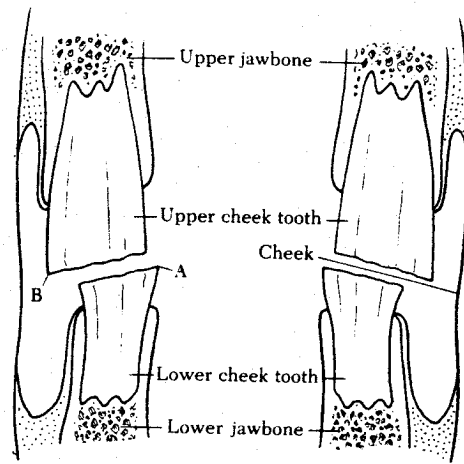


- a. At 9 to 10 years - Galvayne's groove appears at gum margin.
- b. At 15 years - Groove is half-way down labial surface of incisor.
- c. At 20 years - Groove extends entire length of labial surface of incisor.

At 25 years - Groove disappears from upper 1/2 of tooth.

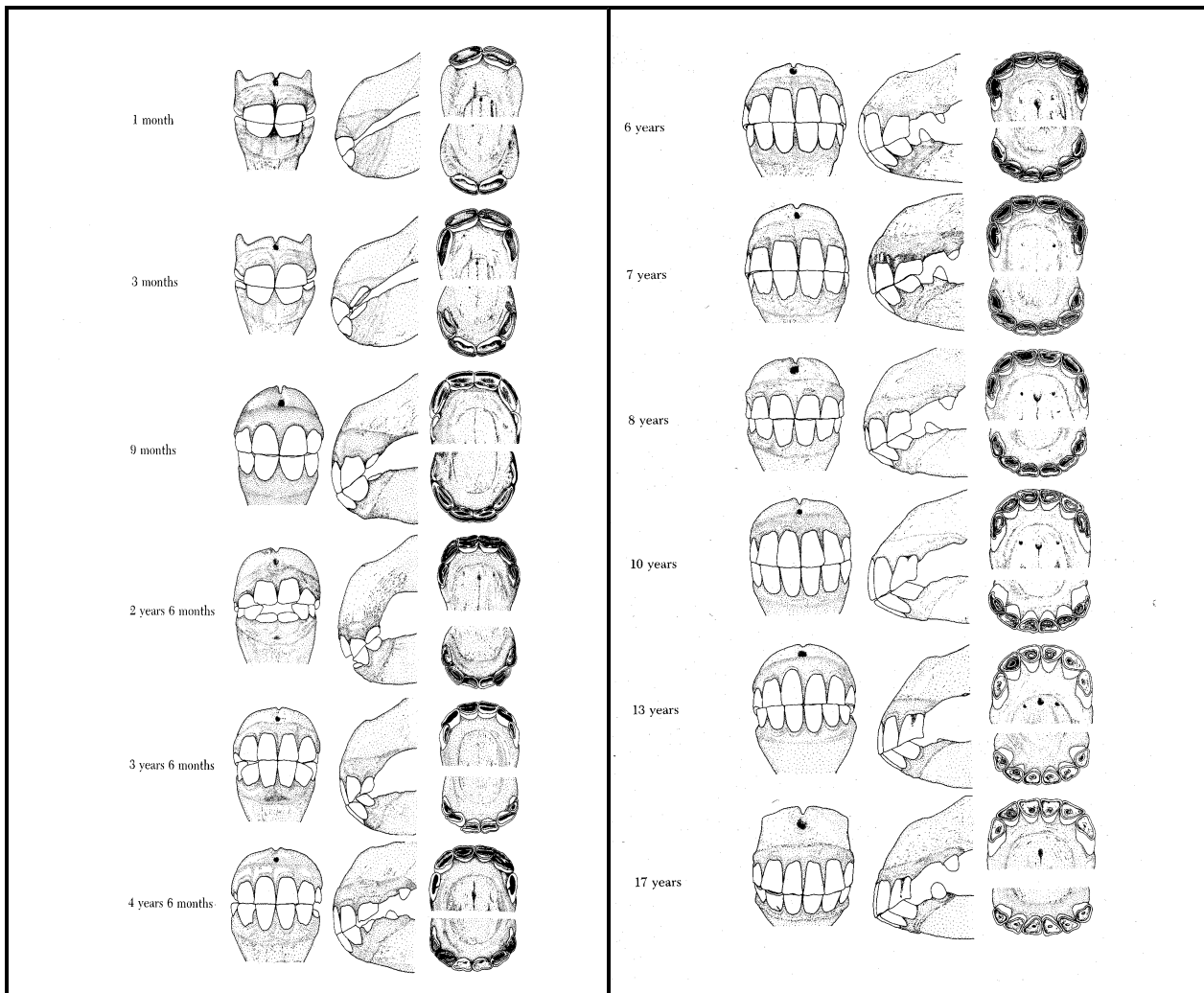
At 30 years - Groove disappears completely from the tooth.

**Figure 4. Molar teeth of horse in cross-section from front**



Constant wear of horizontal and vertical chewing motion produces sharp points (hooks) at A and B. these need to be removed periodically by floating to allow for normal chewing. Note: the table (grinding surface) of the equine molar tooth is not flat.

**Figure 5. Guide to determine age of horse**



To examine the teeth, check the incisive arcade, number of temporary and permanent teeth, and presence or absence of Galvayne's groove. Keep in mind that age determination is only an estimate as environmental factors can influence incisor wear. Horses on soft feeds may appear younger than their actual age. Those on sandy soil pastures or range conditions may appear older because such conditions tend to wear teeth at a faster rate.

**Table 4. Signs of equine dental disease - Idle Horse**

Quidding (loss of food when chewing)	Head tilted
Inefficient chewing	Head shaking
Excessive salivation	Cheek sensitivity
Weight loss/rough hair	Pain when drinking water
Foul odor - mouth/nostrils	Bleeding mouth

**Table 5. Signs of equine dental disease - under saddle**

Poor performance	Tail wringing
Sensitivity to bit	Refusal to stop/turn
Head throwing	Unwilling to collect
Bracing against bit	Poor head carriage

**Equine Dental Conditions:**

- Dental Caps: Retained deciduous teeth after the permanent tooth has erupted: clearly seen after full eruption. Can result in impaction, displacement and prevent normal eruption. May fragment causing laceration/infection of gums, tongue, or cheek. Must be removed.
- Wolf Teeth: Found usually in upper arcade in front of 2<sup>nd</sup> premolar. Often interfere with bit.
- Molar Hook: Occurs as the result of misalignment of the upper and lower jaw so that the upper jaw lies ahead of the lower jaw. Consequently the front of the 2<sup>nd</sup> molar of the upper jaw does not wear against a lower tooth. The tooth continues to grow and forms a hook. In the same manner the rear portion of the last molar of the lower jaw can also develop a hook.
- Parrot Mouth: A congenital condition in which the upper jaw is longer than the lower jaw. The condition results in the development of hooks on upper and lower molar teeth that need to be removed. In addition normal occlusion between the upper and lower incisors is absent and they continue to grow abnormally due to a lack of wear; consequently they must be shortened.
- Wave Mouth: Often occurs in conjunction with parrot mouth, retained dental caps or incisors that are too long. These factors cause a variation in molar height without even contact and wear. Some molars grow longer than other resulting in a wave-like appearance when the molars are viewed from the side.
- Enamel Points: Develop on the outer edges of upper molars and inner edges of the lower molars. Occurs when there is an incomplete overlap of the upper and lower molars and uneven wear on the grinding or biting surfaces during side-to-side chewing.

**Age Specific Dental Care:**

Foal: Shortly after birth the mouth should be examined for congenital problems such as parrot mouth and to insure the normal presence of the incisors and the 2<sup>nd</sup>, 3<sup>rd</sup>, and 4<sup>th</sup> premolars.

2 - 3 Yr. Olds: Check and remove wolf teeth if present. Check 2<sup>nd</sup> and 3<sup>rd</sup> premolars and 1<sup>st</sup> and 2<sup>nd</sup> molars for caps. Float (file or smooth) points

3 Yr. Olds: Check 4<sup>th</sup> premolar and 3<sup>rd</sup> molars. Examine for caps and points. Float if needed.

4 Yr. Old: check 4<sup>th</sup> premolar and 3<sup>rd</sup> molars. Examine for caps and points. Float if needed.

3-4 Yr. Olds: Creation of "bit seat" is often practiced to improve athletic performance. This is rounding and smoothing of the rostral portion of the second premolar. The procedure results in more comfort to the horse when bit action is applied.

Adults: Annual dental exam. Routine dental care. Check for hooks (enamel points) and normal wear of incisors and molar teeth.

Good dental care is essential to the health and well-being of the horse, including performance success and longevity.

#### **References:**

Evans, J. Waner. 1989. *The Horse*. W.H. Freeman & Co., New York.

Gager, E.R. and Rhodes, D. 1983. *Sound Mouth - Sound Horse*. Emerson Publishing Co., New Jersey.

Jeffery, D. 1989. *Equine Dentistry Manual III*. World Wide Equine Dental Supply, Nebraska.

McCue, P. 1998. *Equine Dental Care*. Equine Sciences Newsletter. Colorado State University (19):2.

Wilewski, K.A. and Rubin. L. 1999. *Bit-Seats: A Dental Procedure for Enhancing Performance of Show Horses*. Equine Practice 4(21) pp. 16-20. PO Box 6050 Mission Viejo, CA 92690.

**UNIVERSITY  
OF  
NEVADA**

The University of Nevada, Reno is an Equal Opportunity/Affirmative Action employer and does not discriminate on the basis of race, color, religion, sex, age, creed, national origin, veteran status, physical or mental disability, or sexual orientation, in any program or activity it operates. The University of Nevada employs only United States Citizens and aliens lawfully authorized to work in the United States.